

Maximizing Esthetics with Minimally Invasive Feldspathic Veneers: Combining Digital and Analog Workflows

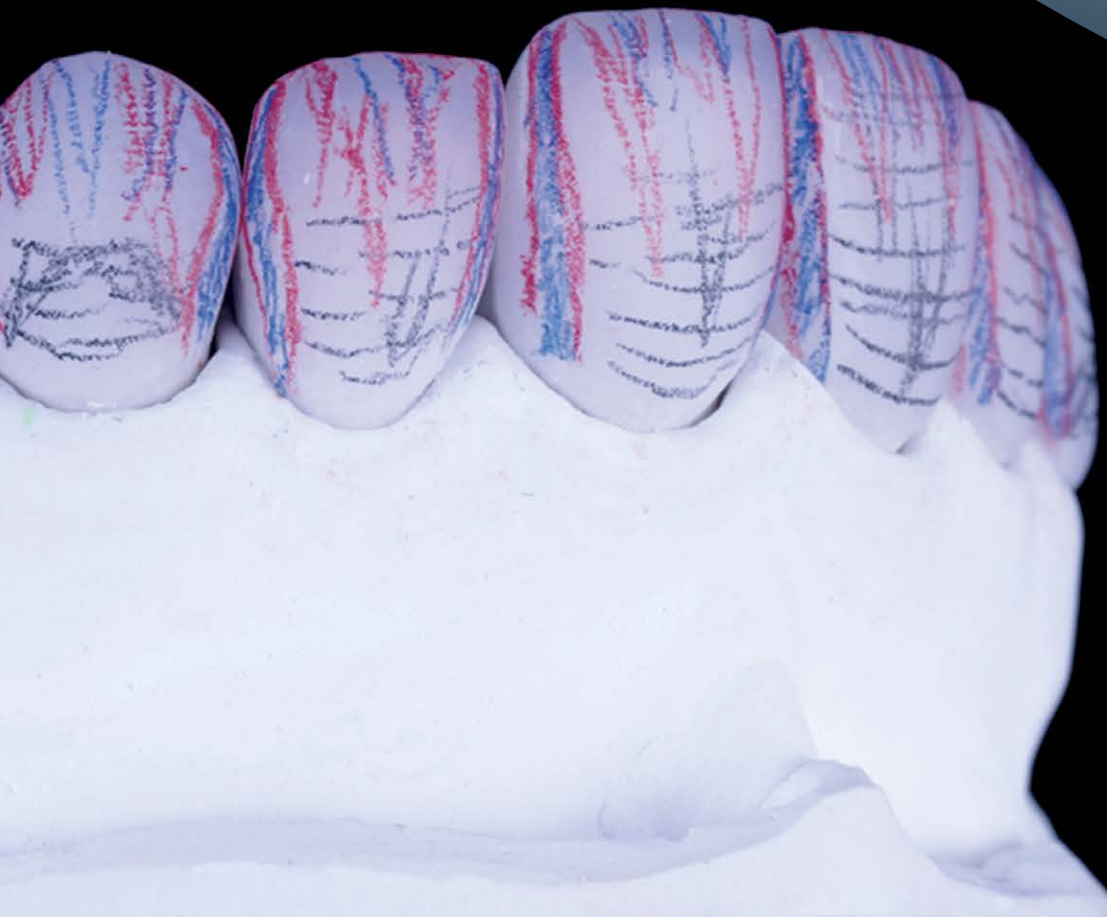Somkiat Aimplee, DDS, MSc, FACP, AAACD
Pannapa Sinthuprasirt, DDS, MMedSci, PhD
Andres Acevedo, MDC
Alvaro Blasi, DDS, CDT
Aram Torosian, MDC, CDT
Gerard J. Chiche, DDS



Abstract

The keys to obtaining predictable and consistent results in esthetic treatment are diagnosis, smile design, treatment planning, team communication, and understanding patient expectations. Digital technology can facilitate this important communication with the patient in order to provide them with a clear understanding of the initial clinical situation, as well as a simulation of the future restoration. The goal of minimally prepared veneers is to preserve as much enamel as possible because bonding to enamel is more predictable than bonding to dentin. This article emphasizes an interdisciplinary approach, digital workflow, minimally invasive treatment, and material selection based on a digital smile design, printing technology for prototype models, and mock-up.

Key Words: digital smile design, interdisciplinary minimally invasive treatment, feldspathic porcelain laminate veneers, crown lengthening, ceramic layering, minimal preparation, digital workflow



CLINICAL COVER CASE

Introduction

The keys to obtaining predictable and consistent results in esthetic treatment are diagnosis, smile design, treatment planning, team communication, and understanding and managing patient expectations. Facially driven esthetic analysis and smile design from the beginning improves communication among team members and enhances the patient's visualization, helping to create a more predictable outcome. At the beginning of each case, accurate treatment planning is required, and it must be clarified whether other interdisciplinary treatment is needed in collaboration with the restorative treatment.

The evolution of ceramic materials has increased and enhanced the minimally invasive treatment options. Ceramic veneers have become a well-established treatment modality for the conservative, highly esthetic restoration of malformed, discolored, malaligned, traumatized, fractured, and/or worn anterior teeth. This concept recommends superficial preparation within the enamel and adhesive luting to facilitate restoration with minimal loss of healthy tooth structure.^{1,2,3}

Treatment with traditional feldspathic porcelain in a thickness of 0.5 to 0.7 mm with the goal of minimal removal of healthy tooth structure has been achieved. Significant advantages of conserving tooth structure include the absence of postoperative sensitivity, better bonding to enamel, minimal flexing stress, long-lasting restorations, potential for reversal, and higher levels of treatment acceptance. Based on data available in the literature, a minimally invasive approach can provide a more esthetic and biologically compatible restoration.⁴⁻⁶

Digital technology can facilitate this important dialogue. The Digital Smile Design (DSD) app (Miami, Florida)^{7,8} and Dental System Software (3Shape; Warren, NJ), printed prototype models and mock-up aim to provide the patient with a clear understanding of the initial clinical situation, as well as a simulation of the future restoration's final result. Patients are more likely to accept treatment when they have a thorough understanding of the clinical problem and the proposed solution.

Case Presentation

A 32-year-old female presented to the office, unhappy with the appearance of her smile, the discolored fillings, and the chipped edges of her front teeth. She also reported additional concerns, including the gingival position, tooth proportion, and wide-open incisal embrasures. The patient had no medical contraindications or allergies (Figs 1-4).



Figure 1: Preoperative full-face frontal view.



Figure 2: Preoperative full-face retracted view.

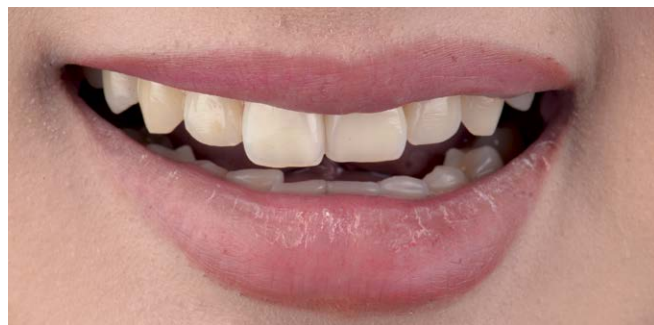

Figure 3: Preoperative close-up smile.

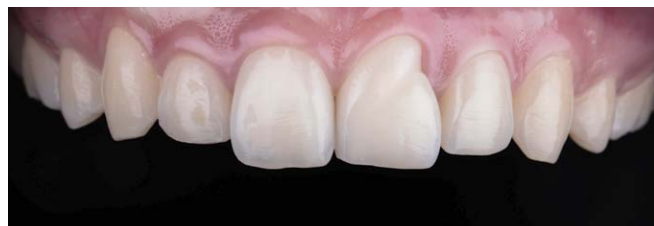

Figure 4: Preoperative retracted frontal view.

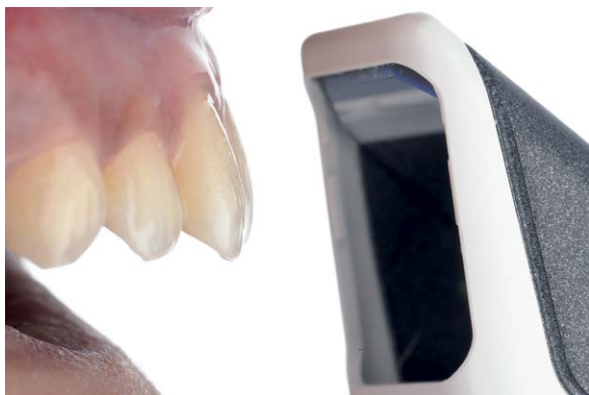

Figure 5: Preoperative intraoral scanning.

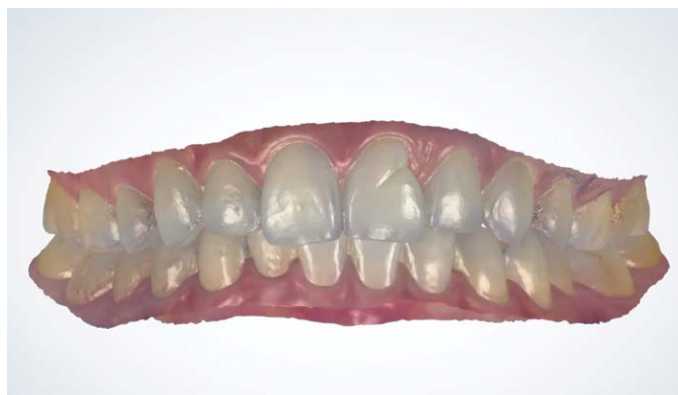

Figure 6: Preoperative intraoral scan image.

Evaluation, Diagnosis, and Treatment Planning

Complete intraoral and extraoral examinations were performed that included evaluation of the hard and soft tissues, temporomandibular joints, periodontal health, occlusion, and the conditions of existing dental restorations. The patient's periodontal health was good, and no parafunctional symptoms were diagnosed. Appropriate initial full-face and close-up photographs were taken to complete the evaluation and support the treatment plan. Clinical evaluation revealed shape alterations affecting the anterior teeth and asymmetrical gingival zenith lines. A diagnostic model of both the maxillary and mandibular arches was obtained by using an intraoral scanner (Trios; 3Shape) and printing technology (Vida, EnvisionTEC; Dearborn, MI) (Figs 5 & 6).

Smile Design Blueprint

Dentists and laboratory technicians must follow a proper step-by-step protocol to achieve a predictable plan for clinical success. Therefore, the treatment plan should begin with a smile design blueprint. In this case, the clinical evaluation revealed that the gingival zenith lines and teeth sizes were asymmetrical.^{9,10} A new gingival zenith and contour were determined for teeth #8 and #9. A smile design blueprint was then designed utilizing the DSD app and Dental System Software in accordance with the correct gingival margin, tooth proportion, and alignment to be established (Figs 7a-8b). The STL files were exported and printed into models. The smile design blueprint model was ultimately used as the prototype for the final restoration (Fig 9).

Mock-Up and Treatment Plan

A mock-up can help to evaluate the patient's esthetic desires and expectations. The mock-up also serves as an effective communication tool for the dentist, patient, and dental laboratory technician. During the mock-up, the esthetic analysis should

include an evaluation of the following oral features: dental midline; facial profile; lip thickness; tooth exposure at rest; incisal curvature; tissue positions; smile width; buccal corridor; phonetics; tooth shape and texture; incisal edge position; individual tooth proportions and contours; occlusal relationship; cant of the occlusal plane; tooth axis; and tooth arrangement.⁹⁻¹¹


A polyvinyl siloxane (PVS) template was made of the smile design blueprint model and used to transfer the prototype to the patient's mouth (Fig 10). The template was loaded with bis-acrylic resin (Protemp Plus shade A1, 3M ESPE; St. Paul, MN) and seated in the mouth for 5 minutes. The template was taken out and excess material carefully removed with a #12D scalpel (Henry Schein; Melville, NY). Photographs were taken and videos made to guide the final treatment plan. Once the desired esthetic, phonetic, and functional outcomes had been verified with the mock-up, the clinical procedures based on the treatment plan—an interdisciplinary minimally invasive approach combining porcelain laminate veneers for teeth #4–13 and crown lengthening—could begin.



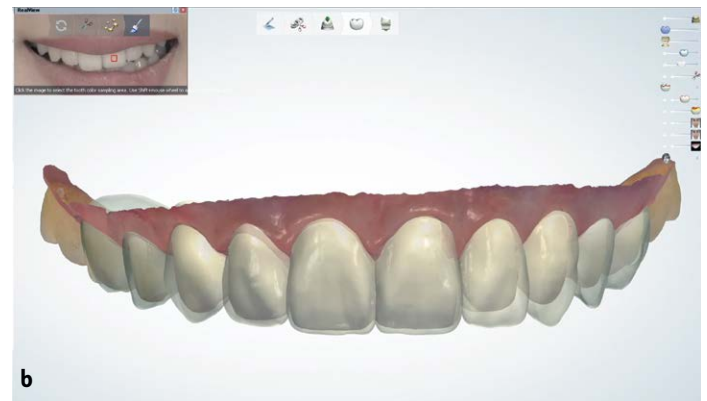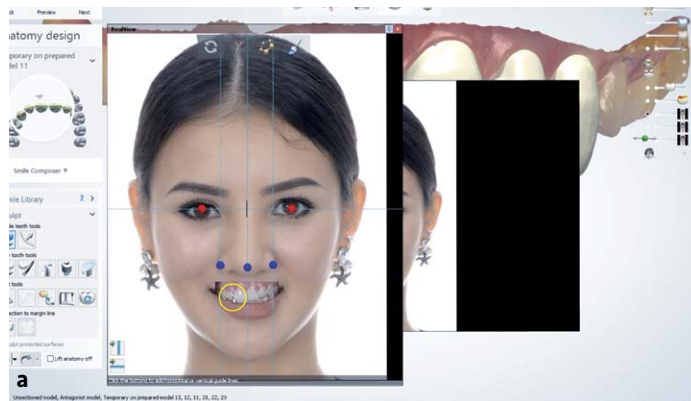
The goal of minimally prepared veneers is to preserve as much enamel as possible because bonding to enamel is more predictable than bonding to dentin.



CLINICAL COVER CASE



Figures 7a & 7b: Digital smile design blueprint.



Figures 8a & 8b: Facially driven smile design using 3D design software.

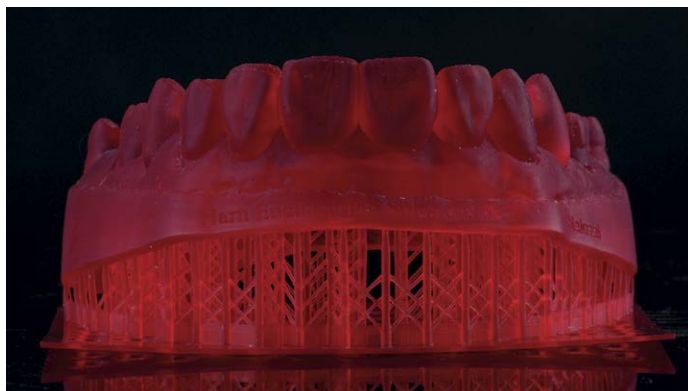


Figure 9: Model printed from the smile design blueprint.

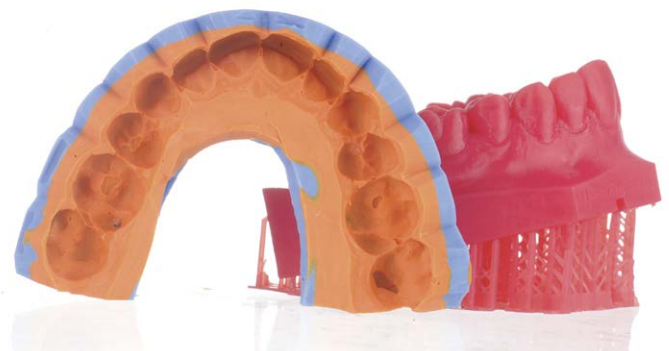


Figure 10: Silicone matrices transferring smile design information to the patient's mouth.

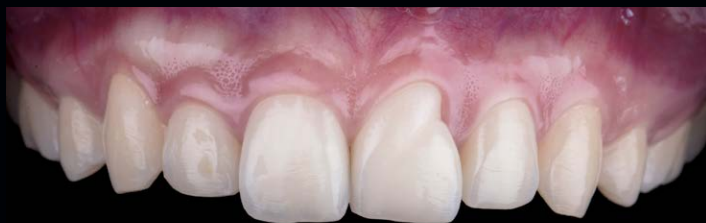

Figure 11: Pre- periodontal surgery frontal view.

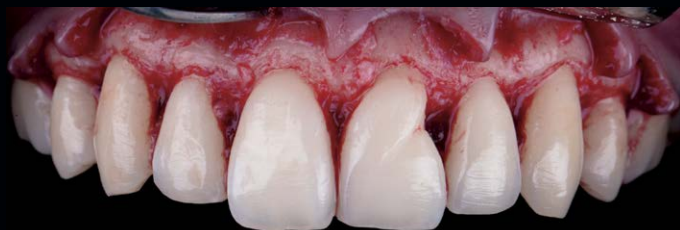

Figure 12: Crown lengthening procedure to level gingival position according to smile design.

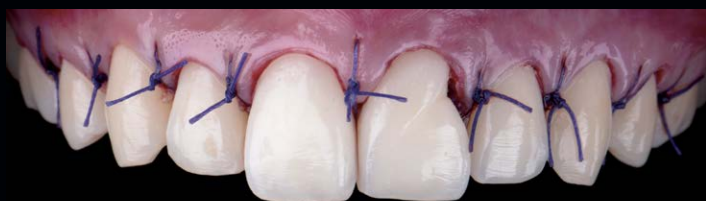

Figure 13: Gingival position after surgery.

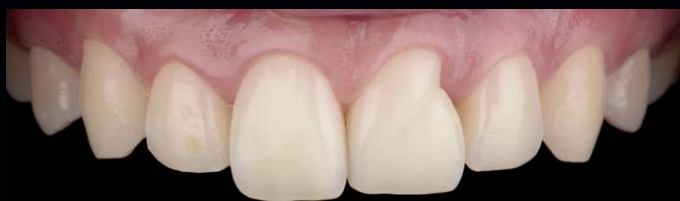

Figure 14: Gingival position after 3 months healing.

Crown Lengthening

Gingival esthetics are critical for a harmonious smile. Different surgical procedures have been used to treat esthetic and functional defects of the gingiva, alveolar mucosa, and bone.¹²

To reproduce the new gingival zenith that had been previously determined, the initial mock-up based on the smile design prototype was maintained in a position to facilitate the crown lengthening of teeth #8 and #9. A gingival outline was cut following the future gingival outline according to the smile design blueprint. A bone probe was used to obtain the biologic width of each tooth. An osteotomy was then performed using appropriate burs and micro-chisels. After the osteotomy, probing was done again to check the final establishment of the biological space (Figs 11-14).

Preparation and Final Impression

Twelve weeks post-surgery, preparations were made via the mock-up using the technique pioneered by Gurel^{5,13} for minimum preparation design and to create a uniform space for the restorative materials that allowed the dentist to visualize the amount of tooth reduction necessary to achieve the esthetic result (Figs 15 & 16).¹⁴ The final preparations, with minimal reduction of teeth and an optimal path of laminate veneer in-

sertion, were accomplished using the Chiche preparation kit (Brasseler USA; Savannah, GA) and finished with Sof-Lex discs (3M ESPE) (Figs 17, 18a-18e); then, the double-mix single-impression technique with PVS (Extrude, Kerr; Orange, CA) was performed (Figs 19a & 19b). Then, tooth preparation shade photographs were taken with the VITA system (VITA) and IPS natural die material shade guide (Ivoclar Vivadent; Amherst, NY) for lab communication (Figs 20 & 21).

Laboratory Procedure

Appropriate restorative planning in this case was based on the principles of using minimally invasive procedures and selecting the most appropriate materials for the final restorations. Based on the substrate preparation color, it was decided to use a feldspathic porcelain material (IPS Style Ceram, Ivoclar Vivadent) with refractory die technique, which allows the fabrication of very thin and heterogeneous laminate veneers that meet the specifications of color, opacity, translucency, and transparency (Figs 22a-22c).

The alveolar "Geller" cast technique was used to retain soft tissue contours while providing an adequate emergence profile for the final restorations (Fig 23).¹⁵

CLINICAL COVER CASE

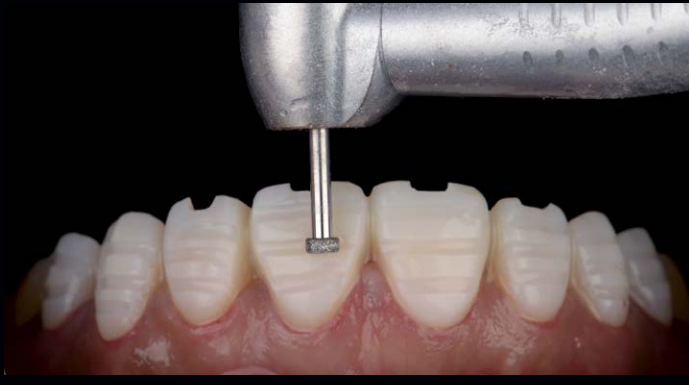

Figure 15: Bis-GMA mock-up as a reference for minimally invasive veneer preparation using 0.3-mm depth cutting bur.

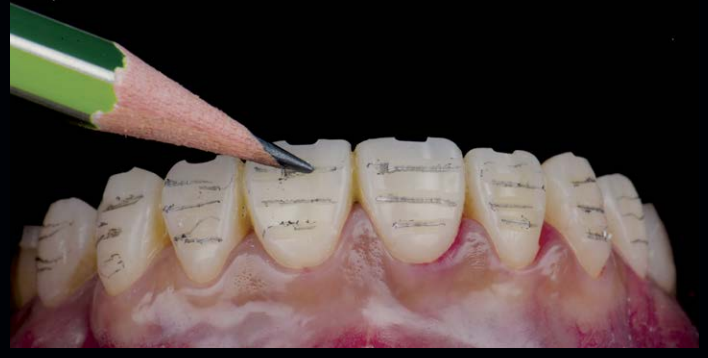

Figure 16: Marking groove to verify the thickness of veneers and use as reference for uniform preparation.

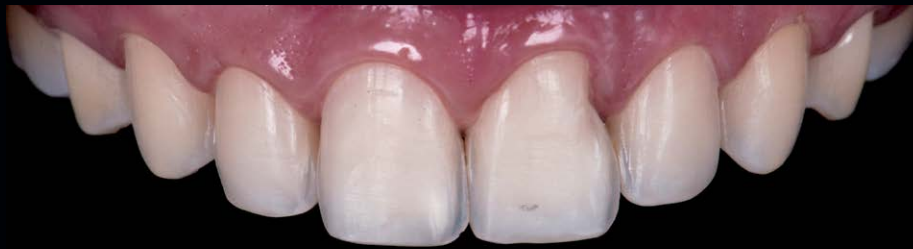
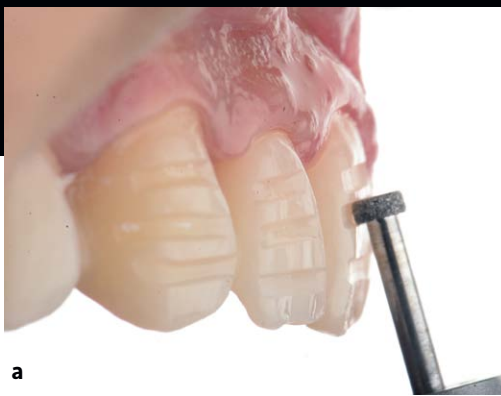
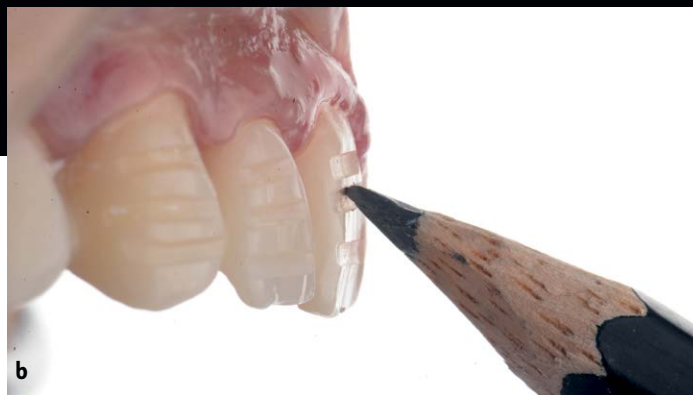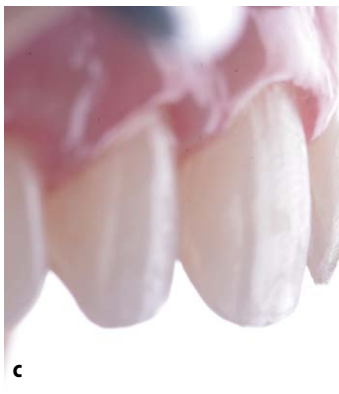Figure 17: Minimally invasive preparation for veneers of 0.5-mm thickness with enamel surface intact.



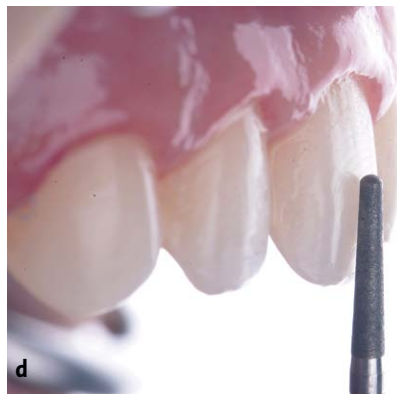
a



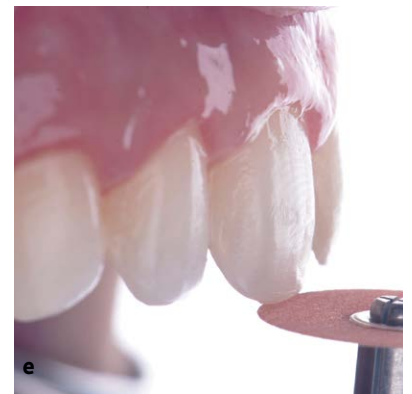b



c

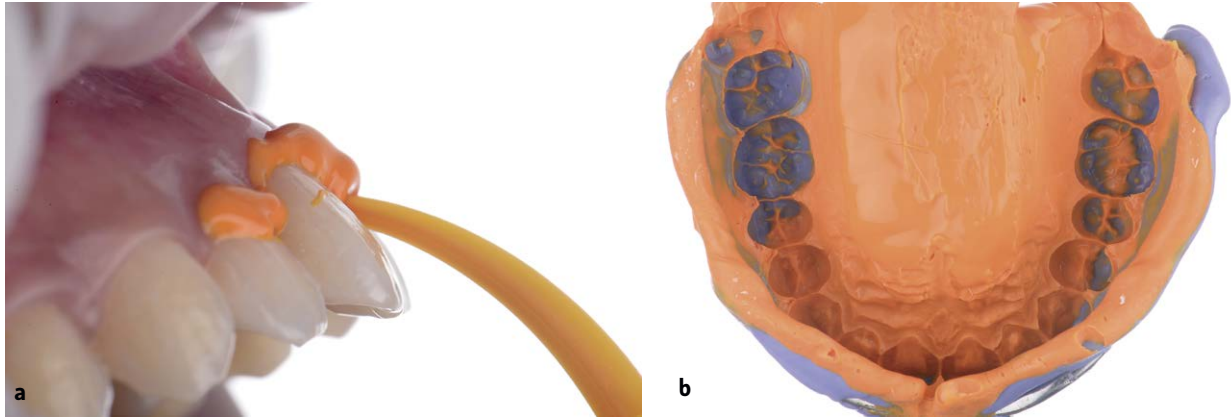


d



e

Figures 18a-18e: Step-by-step veneer preparation.



Figures 19a & 19b: PVS impression.

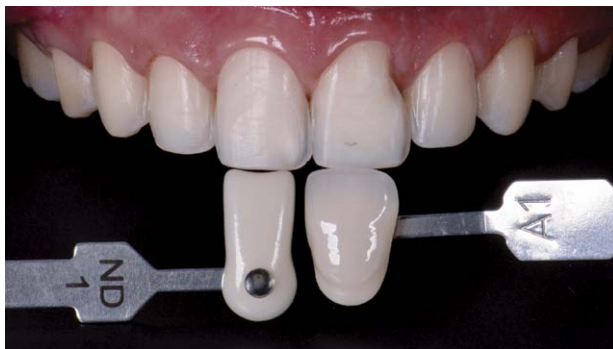

Figure 20: Stump shade photograph for substrate color communication.

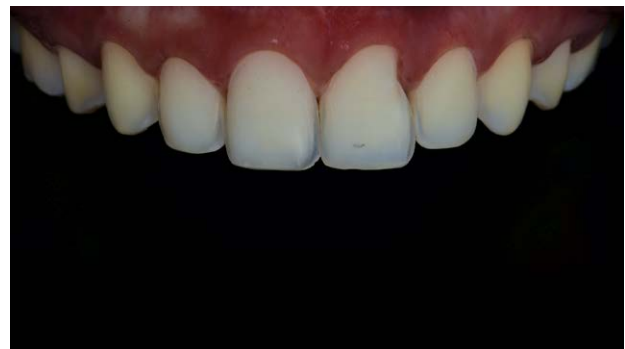
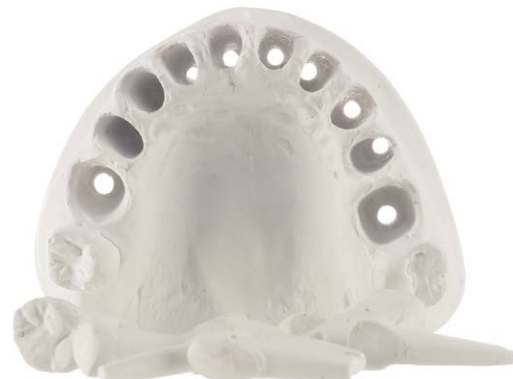
Figure 21: Polarizing filter photograph for technical color communication.



Figures 22a-22c: Ceramic system used to fabricate veneers.

Figure 23: Alveolar (Geller) model to preserve soft tissue information.

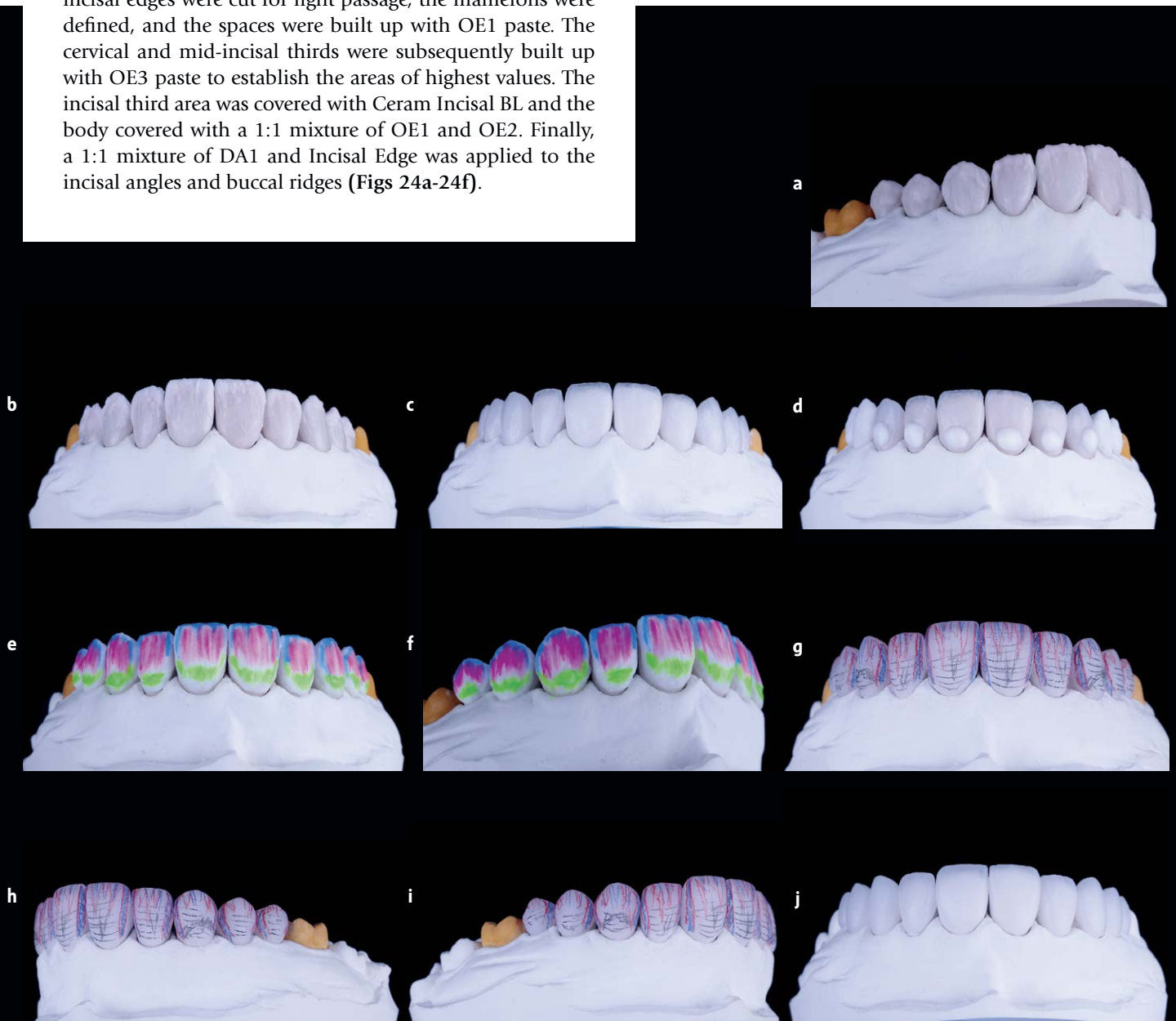


CLINICAL COVER CASE

Ceramic Layering

After hydration of the refractory dies, the ceramic layers were built up with fluorapatite-leucite glass-ceramic materials. A very thin first layer of opalescent ceramic was built up with Opal Effect 1 (OE1) paste. This step was repeated twice to improve sealing. To create the second layer, Deep Dentin (DD) A1 and Dentin Bleach (DBL4) 2 pastes were mixed in a 1:1 ratio. This mixture was used to close the diastemas and compensate for shrinkage at the tooth preparation margins while smoothing the transition from the ceramic layer to the remaining tooth. After achieving optimal tooth length, the incisal edges were cut for light passage, the mamelons were defined, and the spaces were built up with OE1 paste. The cervical and mid-incisal thirds were subsequently built up with OE3 paste to establish the areas of highest values. The incisal third area was covered with Ceram Incisal BL and the body covered with a 1:1 mixture of OE1 and OE2. Finally, a 1:1 mixture of DA1 and Incisal Edge was applied to the incisal angles and buccal ridges (Figs 24a-24f).

The veneers were removed from the refractory dies via sandblasting with 32-micron glass spheres at 1.5 bar pressure, followed by adjustment against the rigid cast. The veneers were 0.5 mm thick in the center and 0.2 mm thick at the margins, with an excellent opalescence resembling a natural tooth (Figs 24g-24j, 25a & 25b).



Figures 24a-24j: Step-by-step layering and contouring the feldspathic porcelain veneers.

Final Cementation of Veneers

Prior to bonding the veneers, the provisional restorations were removed, and the teeth were cleaned with pumice and a prophylaxis brush. The veneers were first seated and eventually adjusted for ideal fit of proximal contacts. Try-in paste (RelyX Veneer TR, 3M ESPE) was used to simulate the post-cementation result, and the patient was allowed to visualize, evaluate, and approve the shade and esthetics prior to bonding. The teeth were air-particle-abraded using 29-micron aluminum oxide (AquaCare, Velopex International; Saint Cloud, FL) to increase micro-mechanism retention. The veneers were rinsed to remove the try-in paste, followed by application of Ivoclean (Ivoclar Vivadent) for 20 seconds to remove saliva and contaminated objects after intraoral try-in, and 9% hydrofluoric acid etch (Ultradent Porcelain Etch, Ultradent, GA) was applied for 90 seconds. After rinsing, ceramic primer (Monobond Plus, Ivoclar Vivadent) and a hydrophilic adhesive resin (Single Bond, 3M ESPE) were then applied and thoroughly air-dried (Figs 26a-26e). An Ultrapak #000 cord (Ultradent) was subsequently placed around each preparation to control sulcular fluid and facilitate cement removal.

The enamel surfaces were etched with 35% phosphoric acid (Scotchbond Phosphoric Etchant, 3M ESPE) for 20 seconds, followed by a thorough 30-second rinsing with water and gentle air-drying for 15 seconds. A hydrophilic adhesive resin (Single Bond, 3M ESPE) was then applied to the enamel surfaces, air-thinned to remove residual solvent and light cured for 20 seconds. The adhesive was also applied to the previously etched internal surfaces of the veneers, and this adhesive was air-thinned to remove residual solvent, but not cured. After adhesive thinning, light-cured luting cement (RelyX Veneer TR, 3M ESPE) was loaded (Figs 27a-27d). The veneers were gently placed on the teeth, and the excess cement was carefully removed from the surfaces and interproximal spaces with artist brushes and dental floss, respectively. The veneers were then photopolymerized for 5 seconds at their cervical margins to tack them in place. Final removal of any residual cement was performed, followed by application of glycerin gel (Liquid Strip, Ivoclar Vivadent) at the margins to prevent formation of an oxygen-inhibited layer.

Definitive photopolymerization was performed facially and palatally for 40 seconds, followed by careful removal of the retraction cords and of any remaining resin cement with a #12D scalpel. Occlusion was evaluated, and interferences in the lateral, lateral protrusive, and protrusive excursions were identified and removed. All finishing and polishing procedures were completed. An occlusal guard to provide night-time protection for the new restorations was fabricated and delivered to the patient at an appointment the following day. The patient returned 2 weeks later for a final check of the restorations, which met the desired esthetic and functional specifications (Figs 28a-28d).




Figures 25a & 25b: Feldspathic porcelain veneers showing translucency with different backgrounds.



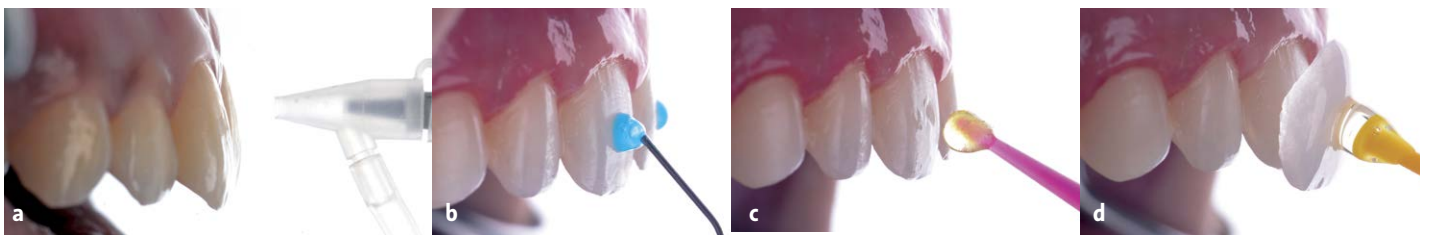
The veneers were 0.5 mm thick in the center and 0.2 mm thick at the margins, with an excellent opalescence resembling a natural tooth.



CLINICAL COVER CASE



Figures 26a-26e: Step-by-step preparation of feldspathic veneer surface with cleaning paste, 9% hydrofluoric acid, ceramic primer, adhesive, and resin cement.



Figures 27a-27d: Step-by-step preparation of tooth surface with 29-micron aluminum oxide sandblasting, 35% phosphoric acid etch, and adhesive.

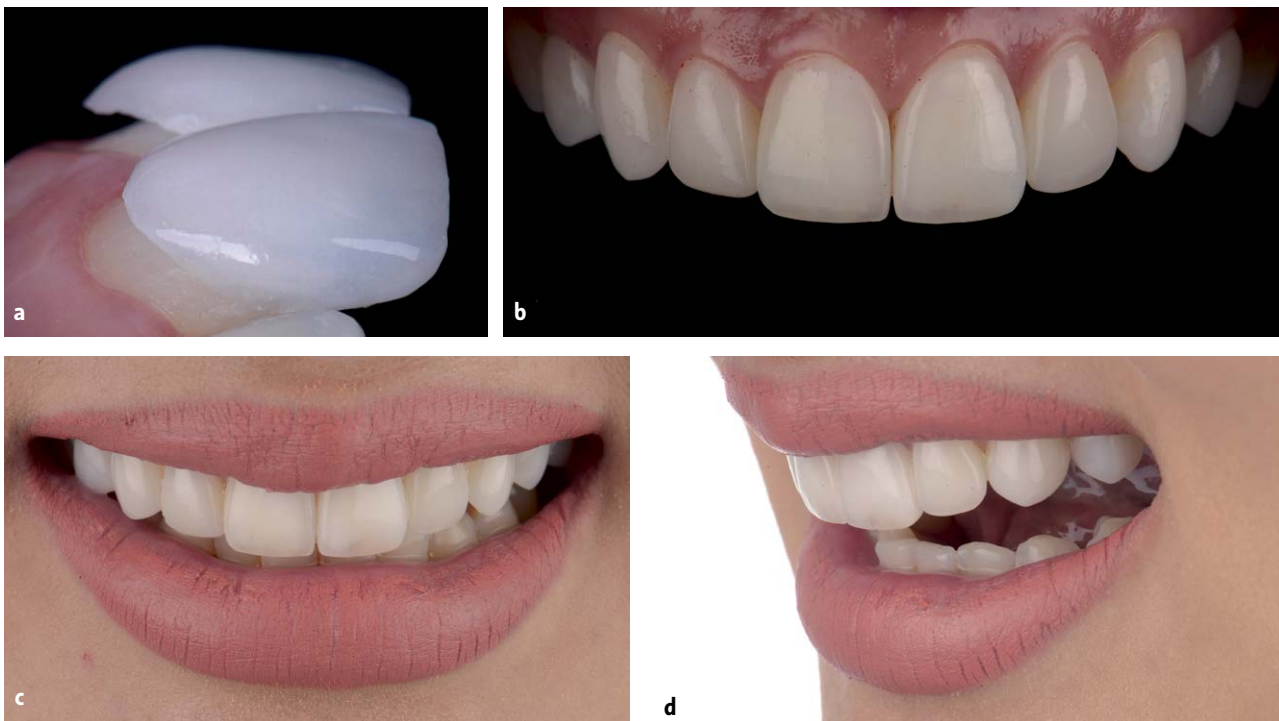


Figure 28a-28d: Final result.



Summary

There are numerous benefits to conservative care, including tooth conservation and longevity; maintenance of periodontal health; and a reduced chance for endodontic consequences. Additionally, porcelain is considered the most esthetic and biocompatible material in dentistry, as it has the capacity to replicate the esthetically pleasing characteristics and vitality of natural teeth.

Ultimately, restorative success must always begin with an appropriate diagnosis, a smile design blueprint, and a well-thought-out treatment plan, which often mandates an interdis-

ciplinary approach. Porcelain veneers produce excellent esthetic results with minimal biological costs and the adhesive technology to warrant a long-term successful result.

This article has demonstrated the use of digital smile design software, a printing technology for prototype models, and a mock-up blueprint that communicates precise minimum tooth reduction and sufficient thickness to the technician in the creation of a natural-looking restoration with feldspathic porcelain material. A natural and facially driven smile design was delivered to the patient.

CLINICAL COVER CASE

References

1. Beier US, Kapferer I, Burtscher D, Dumfahrt H. Clinical performance of porcelain laminate veneers for up to 20 years. *Int J Prosthodont*. 2012 Jan-Feb;25(1):79-85.
2. Fradeani M, Redemagni M, Corrado M. Porcelain laminate veneers: 6- to 12-year clinical evaluation-retrospective study. *Int J Periodontics Restorative Dent*. 2005 Feb;25(1):9-17.
3. Gurel G, Sesma N, Calamita MA, Coachman C, Morimoto S. Influence of enamel preservation on failure rates of porcelain laminate veneers. *Int J Periodontics Restorative Dent*. 2013 Jan-Feb;33(1):31-9.
4. Friedman MJ. Porcelain veneer restorations: a clinician's opinion about a disturbing trend. *J Esthet Restor Dent*. 2001;13(5):318-27.
5. Gürel G. Predictable, precise, and repeatable tooth preparation for porcelain laminate veneers. *Pract Proced Aesthet Dent*. 2003 Jan-Feb;15(1):17-24.
6. Chiche GJ. Proportion, display, and length for successful esthetic planning. In: Cohen M (ed). *Interdisciplinary A Treatment Planning: Principles, Design, Implementation*. Hanover Park (IL): Quintessence Pub.; 2008. p. 21-29.
7. Calamita MA, Coachman C. Virtual esthetic smile design. *J Cosmetic Dent*. 2014 Winter;29(4):102-16.
8. Chiche GJ, Pinault A. Esthetics of anterior fixed prosthodontics. Hanover Park (IL): Quintessence Pub.; 1994. p. 13-32.
9. Gürel G. The science and art of porcelain laminate veneers. Hanover Park (IL): Quintessence Pub.; 2003.
10. Oztürk E, Bolay S. Survival of porcelain laminate veneers with different degrees of dentin exposure: 2-year clinical results. *J Adhes Dent*. 2014 Oct;16(5):481-9.
11. Coachman C. Emotional digital dentistry. *J Cosmetic Dent*. 2019 Winter;34(4):36-42.
12. Jorgensen MG, Nowzari H. Aesthetic crown lengthening. *Periodontology*. 2000. 2001;27(1):45-48.
13. Gurel G. Predictable tooth preparation for porcelain laminate veneers in complicated cases. In: Duarte S, editor. *QDT 2003*. Hanover Park (IL): Quintessence Pub.; 2003. p. 99-111.
14. Calamia JR, Calamia CS. Porcelain laminate veneers: reason for 25 years of success. *Dent Clin North Am*. 2007 Apr;51(2):399-417.
15. Magne M, Bazos P, Magne P. The alveolar model. In: Duarte S, editor. *QDT 2009*. Hanover Park (IL): Quintessence Pub.; 2009. p. 39-46. **jCD**



Dr. Aimplee is an assistant adjunct professor in the Oral Rehabilitation Department at the Augusta University Dental College of Georgia (DCG). He maintains a private practice limited to prosthodontics and esthetic dentistry in Bangkok, Thailand.



Dr. Sinthuprasit is currently a lecturer at Chulabhorn International College of Medicine, Thammasat University, Thailand. She is a specialist in prosthodontics and esthetic dentistry in Bangkok, Thailand.



Mr. Andres Acevedo is a Master Dental Ceramist and maintains a dental laboratory in Madrid, Spain.



Dr. Blasi is a Board Certified Prosthodontist, Dental Technician and Adjunct Assistant Professor in Restorative Sciences Department at Augusta University DCG. He maintains a private practice focused on esthetics and implants in Barcelona, Spain.



Mr. Torosian is a Master Dental Ceramist at the Goldstein Center for Esthetic and Implant Dentistry at the Dental College of Georgia (DCG) at Augusta University, Augusta, Georgia.



Dr. Chiche is a clinical professor at DCG, Augusta University, Augusta, Georgia.



Ultimately, restorative success must always begin with an appropriate diagnosis, a smile design blueprint, and a well-thought-out treatment plan, which often mandates an interdisciplinary approach. ”